



**Pets Have
Teeth Too!**



**NILE POINT
VETERINARY
HOSPITAL**

2007 Niles St.
Bakersfield, CA 93305
ph. (661) 327-9516

Dental Report Card



Date: _____ Doctor: _____

Patient: _____

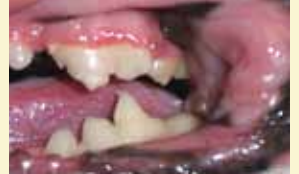When was the last time you looked in your pet's mouth? Pets often go for months and even years with painful gingivitis, fractured teeth or severe tooth root abscesses without noticeable clinical signs to the owner. Proper dental care can potentially add years of life and happiness to your pet.



NICE JOB!

No sign of plaque or tartar. Brushing your pet's teeth regularly is ideal.

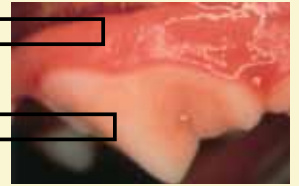
Home dental care is needed to maintain these healthy teeth and gums. There are products available to help make home dental care easier and hassle free.



STAGE 1 – Mild gingivitis: *(reversible stage)*

The margin of attached gum is inflamed and swollen. Plaque can be seen on the teeth.

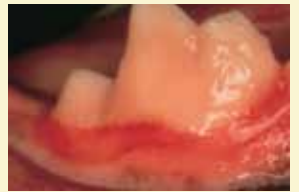
Home dental care is needed. If there is no improvement, dental cleaning is needed to remove current plaque buildup.



STAGE 2 – Moderate gingivitis: *(reversible stage)*

The entire gum is inflamed and swollen. The mouth is painful and odor is noticeable. Infection may start to destroy gum and bone tissue.

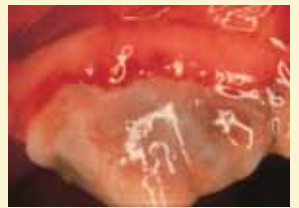Dental cleaning to remove calculus is needed **within the next month**. A calculus control diet and home dental care are needed afterward for prevention.



STAGE 3 – Severe gingivitis: *(potentially reversible stage)*

The gums are cherry red and bleeding – they are damaged by infection and calculus. A sore mouth, loosening of teeth and bad breath are evident.

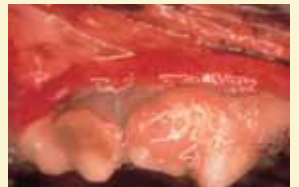
Dental cleaning to remove calculus is needed **immediately**. A calculus control diet and home dental care are needed afterward to prevent recurrence.



STAGE 4 – Periodontal disease: *(irreversible stage)*

Chronic infection is destroying the gums, teeth and bone. Bacteria are spreading through the body via the bloodstream and may damage the kidneys, liver and heart.

Dental cleaning to remove calculus is needed **immediately**. Some teeth may be loose and need extraction. Home dental care afterward is necessary for future prevention.



dental photos courtesy of: Dr. Jan Bellows

Comments: _____
